

Rosmarinic Acid Attenuates Paraquat-Induced Lung Injury by Suppressing Inflammatory Responses in Mice

Mojgan Naghitorabi^{1,2}, Hadis Shayeganfar³, Mohammad Javad Khodayar^{1,3},
Shahzad Molavinia¹, Mehrnoosh Moosavi^{1,3}, Layasadat Khorsandi⁴,
Maryam Salehcheh^{*1,3}

Abstract

Background: Paraquat (PQ) is a commonly used herbicide known for its high toxicity. Despite its hazardous nature, there are currently no effective treatments for PQ poisoning. This study aimed to evaluate the effects of Rosmarinic acid (RA), a phenolic compound, on PQ-induced lung injury in mice.

Methods: Mice were divided into ten groups for two experimental periods, 6- and 24-day periods (five groups each). The first group received normal saline daily, as the control group. Animals in the second group received a single intraperitoneal (i.p.) dose of PQ (25 mg/kg) on day 3. Groups three and four received RA (50 and 100 mg/kg, respectively) orally for 6 or 24 days. Group five received 100 mg/kg of RA daily. Animals were sacrificed 24 h after the last treatment, and lung samples were collected to determine histopathological changes and expression of TLR9, IL-1 β , and TNF- α genes using RT-PCR.

Results: Hematoxylin and eosin staining revealed a significant reduction in lung injury following RA treatment. RA notably reduced inflammatory cell infiltration and lung tissue congestion. Furthermore, inflammatory responses triggered by PQ were suppressed after RA treatment, as demonstrated by the downregulation of IL-1 β , TNF- α , and TLR9 levels.

Conclusion: These findings suggest the therapeutic potential of RA for mitigating PQ-induced lung damage and inflammation.

Keywords: Inflammation, Lung, Phenols, Mice, Paraquat.

Introduction

Paraquat (PQ) is one of the most common herbicides used for weed control in agriculture and has adverse effects on human health, particularly on the respiratory system (1). It causes specific cellular damage through a nicotinamide adenine dinucleotide phosphate (NADPH)-dependent mechanism, leading to lipid peroxidation, mitochondrial dysfunction, and the overproduction of intracellular free radicals (2). Lung damage caused by PQ is

marked by a destructive phase occurring within days, which results in damaged cellular structures, pulmonary hemorrhage, fluid accumulation, and inflammatory responses (3). The final stage occurs approximately 14–21 days after PQ exposure (4). During this phase, the inflammatory processes produce excessive extracellular matrix components, such as collagen, in the lung parenchyma (5). The second phase signifies chronic and irreversible

1: Toxicology Research Center, Medical Basic Sciences Research Institute, Ahvaz Jundishapur University of Medical Sciences, Ahvaz, Iran.

2: Department of Pharmacognosy, School of Pharmacy, Ahvaz Jundishapur University of Medical Sciences, Ahvaz, Iran.

3: Department of Toxicology, School of Pharmacy, Ahvaz Jundishapur University of Medical Sciences, Ahvaz, Iran.

4: Cellular and Molecular Research Center, Medical Basic Sciences Research Institute, Ahvaz Jundishapur University of Medical Sciences, Ahvaz, Iran.

*Corresponding author: Maryam Salehcheh; Tel: +98 9166075337; E-mail: salehcheh-m@ajums.ac.ir.

Received: 14 Feb, 2025; Accepted: 7 Jul, 2025

changes in the lungs following PQ-induced damage (6). Currently, there is no effective treatment for PQ poisoning, underscoring the urgent need for further research in this area. Researchers are investigating strategies to alleviate the respiratory symptoms induced by PQ and improve patient outcomes. These strategies focus on developing innovative treatments to reduce PQ toxicity, including anti-inflammatory agents, antioxidants, and compounds that promote lung repair (5, 6).

Rosmarinic acid (RA) is a phenolic compound composed of a 3,4-dihydroxy lactic acid caffeic acid ester, first isolated from *Rosmarinus officinalis* L., a plant belonging to the Lamiaceae family (7). It exhibits several biological activities, including antioxidant, anti-inflammatory, antimutagenic, anti-apoptotic, antibacterial, and antiviral properties (8,9). Rosmarinic acid (RA) attenuates reactive oxygen species production by inhibiting caspase-3 activity, thereby reducing mitochondrial outer membrane permeability alterations (10). It exerts anti-inflammatory effects and reduces the activity of inflammatory factors such as tumor necrosis factor-alpha (TNF- α), interleukin-1 beta (IL-1 β), and interleukin-6 (IL-6) (11). Moreover, recent studies suggest that RA influences the Toll-like receptor (TLR) signaling pathway, a crucial component of the innate immune system responsible for recognizing specific molecular patterns associated with pathogens (12,13). These findings suggest that RA could represent a potential therapeutic approach for treating PQ-induced lung injury. Therefore, this study aims to explore whether RA can mitigate PQ-induced lung damage in mice by investigating both biochemical and histopathological alterations.

Materials and Methods

Chemicals

Paraquat (PQ) and Rosmarinic acid (RA) were purchased from Merck (Germany) and Sigma-Aldrich (USA). All the compounds were dissolved in saline. Doses were chosen based on previous studies (14,15).

Animals

Sixty male NMRI albino mice, initially weighing between 25–30 g, were obtained from the animal house of Ahvaz Jundishapur University of Medical Sciences, Iran. The mice were kept under standard conditions of 23 ± 2 °C and 12-hour light/dark cycles and were provided *ad libitum* access to food and water.

Ethical Consideration

All protocols were approved by the Research Ethics Committee of Ahvaz Jundishapur University of Medical Sciences (Ethical code: IR.AJUMS.ABHC.REC.1397.031), which is affiliated with the National Institutes of Health.

Study design

The study was conducted during the 6- and 24-day periods, with mice divided into five groups for each experimental period (n=6) and treated as follows:

Group I: Received saline daily.

Group II: Received a single dose of PQ (25 mg/kg, i.p.) on day 3.

Groups III and IV: Received 50 mg/kg and 100 mg/kg of RA for 6 or 24 days, respectively.

Group V: Received 100 mg/kg of RA daily.

Sample Collection

Mice were anesthetized with ketamine and xylazine (100/10 mg/kg, Alfasan, Netherlands) 24 h after the last treatment (16). Surgical procedures, including opening the chest and immediate removal of the lungs, were performed under anesthesia. The right lung was used to evaluate gene expression, and the left lung was used for histological analysis.

RNA extraction and real-time polymerase chain reaction (RT-PCR)

The lung tissues were stored at -80 °C until total RNA was isolated. According to the manufacturer's instructions, total RNA was isolated from homogenized tissues using an RNX-Plus solution (CinnaGen, Iran). Isolated RNA concentrations were measured by determining absorbance at 260 nm using a spectrophotometer (NanoDrop 1000, Thermo

Scientific). According to the manufacturer's instructions, cDNA was synthesized from isolated RNA using a cDNA synthesis kit (Fermentas, Canada). Relative expression of TLR9 (NCBI reference sequence NM_031178.2), IL-1 β (NCBI reference sequence NM_008361.4), and TNF- α (NCBI reference sequence NM_013693.2) was normalized to that of the housekeeping gene β -actin (NCBI reference sequence NM_007393.3) and analyzed by the $2^{-\Delta\Delta Ct}$ method. Primer sequences were as follows:
 β -actin forward,
 5'-GGCTGTATCCCCTCCATCG-3';
 β -actin reverse,
 5'-CCAGTTGGTAACAATGCCATGT-3';
 TLR9 forward,
 5'-ATGGTTCTCCGTCGAAGGACT-3';
 TLR9 reverse,
 5'-GAGGCTTCAGCTCACAGGG-3';
 IL-1 β forward,
 5'-GCAACTGTTCCCTGAACTCAACT-3';
 IL-1 β reverse,
 5'-ATCTTTTGGGGTCCGTCAACT-3';
 TNF- α forward,
 5'-CACAGAAAGCATGATCCGCG-3';
 TNF- α reverse,
 5'-GAGGCTGAGACATAGGCACC-3'.
 RT-PCR amplification was performed in 45 cycles under the following conditions: 95 °C for 15 min, 95 °C for 15 s, 60 °C for 35 s, and 72 °C for 10 s.

Histopathological assessment

One part of the lung tissue was fixed in 10% formalin (Merck, Germany) and embedded in paraffin. Paraffin-embedded tissue sections (5 μ m) were obtained and subjected to hematoxylin and eosin (H&E, Merck, Germany) staining. These sections were then examined under a photomicroscope (Olympus, Japan) to detect congestion, inflammatory cell infiltration, and histopathological changes (17).

Statistical analysis

GraphPad Prism (version 9, CA, USA) was used for the data analysis. Results are expressed as mean \pm SEM, and all statistical

comparisons were conducted using one-way ANOVA followed by Tukey's post hoc analysis. Statistical significance was set at $p < 0.05$.

Results

No animal mortality due to PQ treatment was observed in the current study.

Results of TLR9, IL-1 β , and TNF- α gene expression

The RT-PCR assay evaluated TLR9, IL-1 β , and TNF- α gene expression in lung tissue in the 6-day and 24-day studies. The PQ group exhibited significant changes in TLR9 gene expression compared with the control group in the 24-day study ($p < 0.05$) (Fig. 1). Rosmarinic acid (RA) administration (50 and 100 mg/kg) significantly reduced TLR9 expression compared to the PQ group ($p < 0.05$ and $p < 0.01$). These changes in gene expression in the RA-treated groups indicate the potential of RA to mitigate lung tissue damage. A substantial increase in IL-1 β gene expression in the PQ group compared to the control group in the 6 and 24-day studies ($p < 0.001$) (Fig. 2) was found. The RA-treated groups, at doses of 50 and 100 mg/kg, showed a significant decrease compared to the PQ group after 3 and 21 days of PQ exposure ($p < 0.001$). This substantial decrease in gene expression in the RA-treated groups provides reassurance regarding the potential effectiveness of RA treatment strategies. A significant elevation in TNF- α gene expression was noted in the PQ group, in stark contrast to the control group, at both 6 and 24 days ($p < 0.001$) (Fig. 3). RA-treated groups (50 and 100 mg/kg) exhibited a significant decrease compared to the PQ group ($p < 0.05$, $p < 0.01$ and $p < 0.001$).

Histopathological examination

Histopathological analysis of the lungs of PQ-exposed mice revealed significant findings in both studies (Fig. 4, Tables 1 & 2). Lesions, congestion, and inflammatory cell infiltration were observed in the PQ-exposed group. Lesions refer to any abnormality or damage in the tissue, congestion is the accumulation of

blood or fluid; and inflammatory cell infiltration is the migration of immune cells to the site of injury. In contrast, the lungs of the control groups (saline or RA 100 mg/kg) appeared normal without any abnormalities in either study. In the 24-day study, treatment with RA at a 50 mg/kg dose significantly

reduced PQ-induced congestion ($p < 0.01$). However, in the 6-day study, the PQ + RA50 group showed improvement in inflammation ($p < 0.001$). In the 6-day and 24-day studies, the PQ + RA100 group showed improvement in inflammatory cell infiltration and congestion ($p < 0.01$, $p < 0.001$).

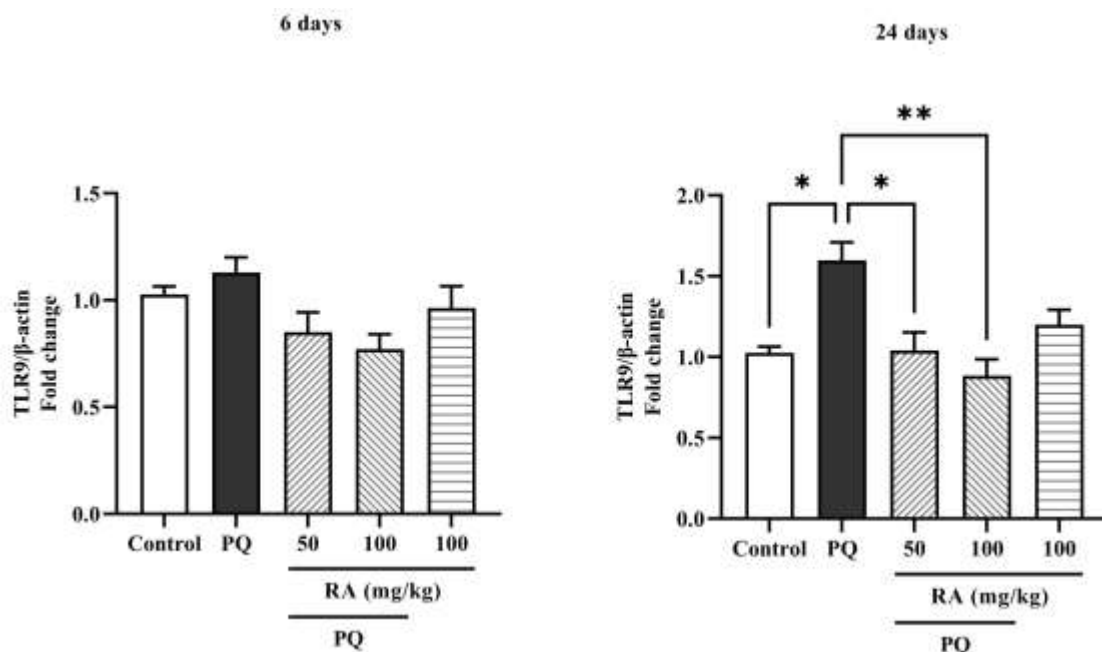


Fig. 1. Comparison of TLR9 levels in lung tissue samples collected from mice 24 h after the last treatment. The relative changes in TLR9 levels were expressed as TLR9 to β -actin ratio. PQ: Paraquat, RA: Rosmarinic acid, TLR: Toll-like receptor. Each value represents the mean \pm SEM ($n=6$). (* $P < 0.05$ and ** $P < 0.01$).

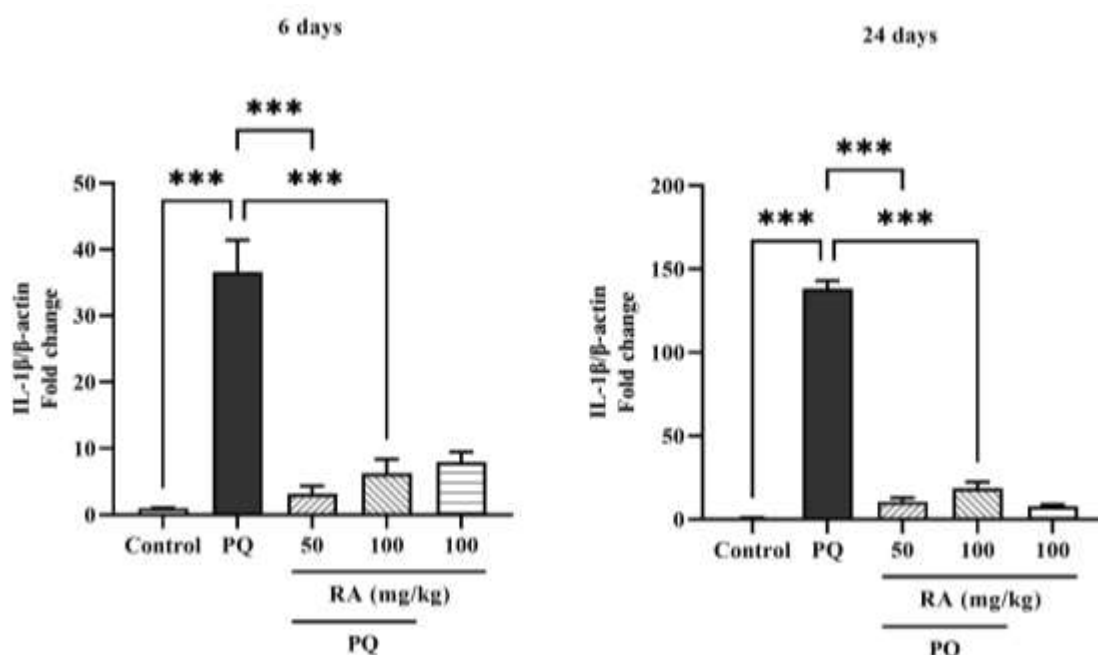


Fig. 2. Comparison of IL-1 β levels in lung tissue samples collected from mice 24 h after the last treatment. The relative changes in IL-1 β levels were expressed as the IL-1 β to β -actin ratio. PQ: Paraquat, RA: Rosmarinic acid, IL-1 β : interleukin-1 beta. Each value represents the mean \pm SEM ($n=6$) (***) $p < 0.001$).

Rosmarinic Acid Reduces Paraquat Lung Injury

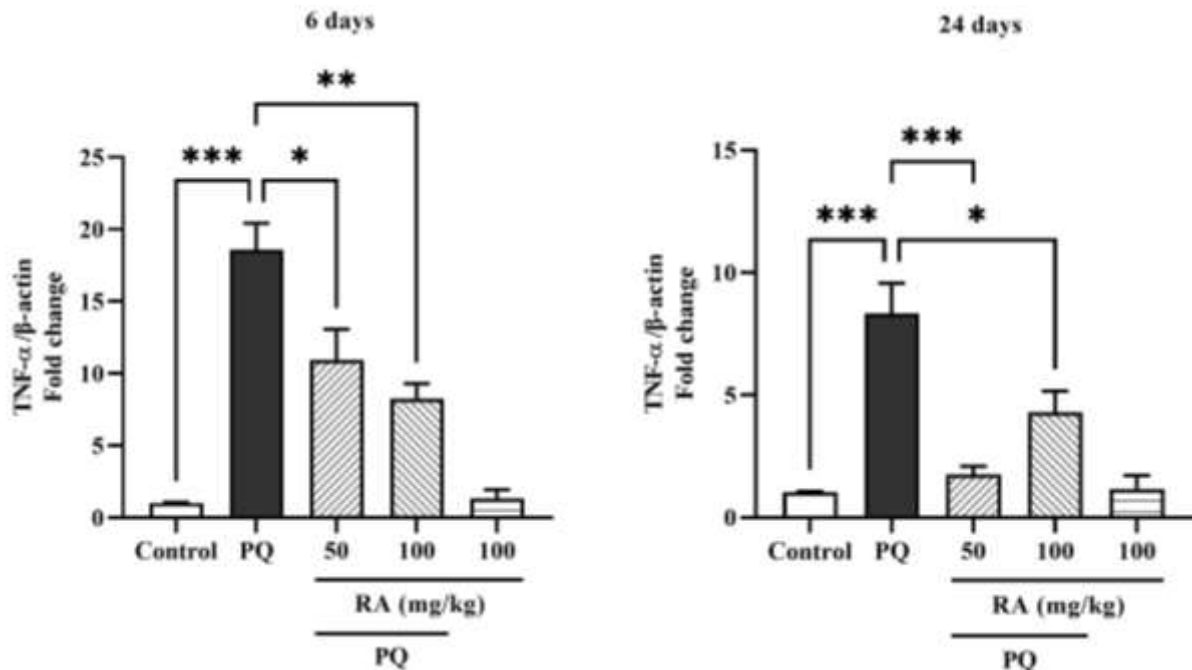


Fig. 3. Comparison of TNF- α levels in lung tissue samples collected from mice 24 h after the last treatment. The relative changes in TNF- α levels were expressed as the TNF- α to β -actin ratio. PQ: Paraquat, RA: Rosmarinic acid, TNF- α : tumor necrosis factor alpha. Each value represents the mean \pm SEM (n=6) (*p< 0.05, **p< 0.01 and ***p< 0.001).

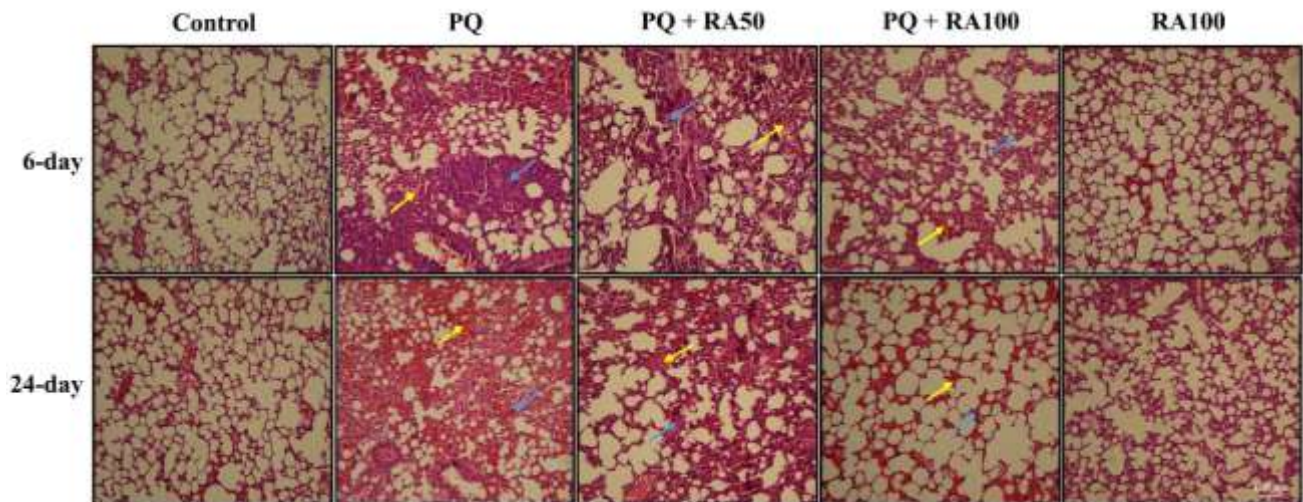


Fig. 4. Histopathological observation of lung tissues was performed by staining with hematoxylin and eosin (H&E, magnification 100x, scale bars 100 μ m). PQ: Paraquat, RA: Rosmarinic acid. Blue arrows: inflammatory cell infiltration, yellow arrows: congestion.

Table 1. The effects of PQ and RA on histopathological parameters in the 6-day study.

Groups	Congestion	Inflammatory cell infiltration
Control	0.07 \pm 0.03	0.06 \pm 0.02
PQ	1.52 \pm 0.24***	2.68 \pm 0.38***
PQ + RA50	1.43 \pm 0.23	1.18 \pm 0.24###
PQ + RA100	0.36 \pm 0.06###	0.21 \pm 0.03###
RA100	0.05 \pm 0.01	0.03 \pm 0.00

PQ: Paraquat, RA: Rosmarinic acid. Each value represents the mean \pm SEM (n=6). * Statistical differences vs. control group (**p< 0.001), # statistical differences vs. PQ group (### p< 0.001).

Table 2. The effects of PQ and RA on histopathological parameters in the 24-day study.

Groups	Congestion	Inflammatory cell infiltration
Control	0.07 ± 0.02	0.05 ± 0.02
PQ	2.76 ± 0.31***	1.15 ± 0.24**
PQ + RA50	1.54 ± 0.28##	0.48 ± 0.14
PQ + RA100	1.01 ± 0.18###	0.12 ± 0.24###
RA100	0.06 ± 0.02	0.04 ± 0.00

PQ: Paraquat, RA: Rosmarinic acid. Each value represents the mean ± SEM (n=6). * Statistical differences vs. control group (**p < 0.01, ***p < 0.001). # statistical differences vs. PQ group (## p < 0.01, ### p < 0.001).

Discussion

This study demonstrated that RA significantly ameliorated the PQ-induced pulmonary injury in mice. This protective effect is evidenced by reduced inflammatory cell infiltration, decreased lung congestion, and notably, the down-regulation of TLR9, IL-1 β , and TNF- α gene expression. Collectively, these findings suggest that RA possesses promising therapeutic potential against PQ-induced lung damage.

Our observation of lung injury following PQ treatment aligns with a previous study by Molavinia *et al.* (18). They reported that a single dose of PQ (20 mg/kg, *i.p.*) induced fibrotic lesions, including hydroxyproline deposition, inflammatory cell infiltration, and congestion after three weeks of treatment in rats. Our study extends these findings by demonstrating the protective effects of RA against PQ-induced abnormalities, underscoring the importance of our research in this field. Unlike studies focusing solely on the acute effects of PQ, we examined both the 6-day and 24-day experimental periods to observe the development of lung damage over time, as previously described (19,20). This allowed us to assess the impact of RA on both the early and later phases of PQ-induced lung injury.

Rosmarinic acid (RA) has been shown to exhibit anti-inflammatory and antioxidant activities in various animal models. A recent study demonstrated that RA, an antioxidant, protects against pulmonary ischemia/reperfusion injury in mice. It improved hypoxemia, pulmonary edema, and inflammatory cytokine levels while reducing pro-oxidant NADPH oxidases and enhancing antioxidant superoxide dismutase. It also

activated the phosphatidylinositol 3-kinase/Akt pathway to decrease reactive oxygen species and lower alveolar epithelial cell apoptosis, highlighting its potential as a treatment for pulmonary injury (19). In a mouse asthma model, RA treatment significantly reduced inflammatory cell numbers, T helper 2 cytokine production, and airway hyperresponsiveness, suggesting that RA is a potential therapeutic agent for allergic asthma (20). Another study also found that RA significantly reduced inflammatory cell numbers and cytokine production via the modulation of NADPH oxidases (21). Given that PQ produces free radicals and superoxide anions via NADPH-dependent single-electron reduction (22), RA may be a promising approach to address this issue, offering hope for the development of effective treatments for pulmonary diseases.

A key finding of our study was the reduction in TLR9 expression following RA treatment. TLRs are key components of the host immune system and can initiate immune responses against invading pathogens and non-microbial endogenous molecules that originate from tissue damage (21). Studies have shown that the expression of TLR4 and TLR9 is increased in PQ-induced acute tissue injury, which is related to the extent and severity of the injury (22, 23). Our findings are consistent with those of Qian *et al.* (24), who found that the expression of TLR9 in the lung significantly increases in pulmonary fibrosis and is associated with the severity of lung damage caused by PQ in mice. Similarly, Shen *et al.* (25) showed that TLR9 expression was elevated following PQ poisoning and that TLR9 knockout mitigated PQ-induced lung injury. Our results build upon these studies by suggesting that RA's protective

effects may be mediated through the modulation of TLR9 expression. This aligns with research demonstrating that RA can reduce inflammatory reactions by inhibiting high-mobility group box 1 (HMGB1), TLR4, and nuclear factor kappa-B signaling pathway and decreasing the generation of pro-inflammatory cytokines (26). Given that TLRs play a crucial role in immune response and inflammation, it is plausible that RA could potentially impact TLR signaling, including TLR9. Our findings revealed that RA can reduce the expression of TLR9, suggesting the potential for further exploration of RA as a therapeutic agent in conditions where TLR9 activation plays a significant role.

Furthermore, we observed that RA treatment significantly reduced the levels of IL-1 β and TNF- α during both phases of PQ-induced lung injury. PQ interferes with the mitochondrial electron transport chain, causing mitochondrial DNA (mtDNA) to leak into the cytoplasm (27). Given its lack of methylation, mtDNA is likely recognized by TLR9, triggering subsequent inflammatory signaling pathways (28). It is known that several genes are expressed during inflammation, leading to fibroblast proliferation and increased collagen levels, resulting leading to pulmonary failure (29). As previously reported, administration of PQ at a dose of 20 mg/kg increases lung injury by increasing cytokines, chemokines, and growth factors in mice (30). The results of the current study indicate that PQ administration causes a significant reduction in the expression of IL-1 β and TNF- α , which is consistent with previous studies (31, 32). Our results are consistent with previous studies showing that RA exerts anti-inflammatory effects by decreasing TNF- α , IL-6, and IL-1 β levels in a lipopolysaccharide model of lung injury in mice (33). These results support the idea that RA's protective effects are linked to its anti-inflammatory properties, providing further evidence for its potential therapeutic use in treating inflammatory lung injury conditions.

While our study provides valuable insights into the therapeutic effects of RA on PQ-induced lung injury, it is essential to

acknowledge its limitations. Future studies should focus on elucidating the precise mechanisms of RA's action and conducting clinical trials to validate its effectiveness in treating pulmonary diseases in humans. Such research will pave the way for developing novel therapies and guidelines for clinical diagnosis and treatment.

Our findings underscore the potential of RA to protect against lung injury induced by PQ at various stages of PQ toxicity. This study provides compelling evidence that RA modulates inflammatory responses, as demonstrated by the downregulation of IL-1 β , TNF- α , and TLR9. These results encourage further research on RA as a promising therapeutic agent for treating PQ-induced lung injury.

Funding information

This work received financial support from the Toxicology Research Center, Medical Basic Sciences Research Institute, Ahvaz Jundishapur University of Medical Sciences in Ahvaz, Iran (Grant Number: TRC-9713).

Conflict of interest statement

The authors declare that there is no conflict of interest.

Acknowledgment

This article is derived from the Pharm.D. thesis of Hadis Shayeganfar and was supported by Ahvaz Jundishapur University of Medical Sciences.

Authors' Contributions

M. N. designed the study, contributed to experiments, and supervised the project. H. Sh performed the experiments and curated the data. M. J. Kh. contributed to the experiments and methodology. Sh. M. analyzed the data, prepared the figures, and wrote the manuscript. M. M. supervised the project. L. Kh. interpreted the pathology data. M. S. conceptualized the study, contributed to methodology, supervised the project, and managed project administration. All authors read and approved the final manuscript.

References

- Amin F, Roohbakhsh A, Memarzia A, Kazerani HR, Boskabady MH. Immediate and late systemic and lung effects of inhaled paraquat in rats. *J Hazard Mater.* 2021;415:125633.
- Martemucci G, Costagliola C, Mariano M, D'andrea L, Napolitano P, D'Alessandro AG. Free Radical Properties, Source and Targets, Antioxidant Consumption and Health. *Oxygen.* 2022;2(2):48–78.
- Dinis-Oliveira RJ, Duarte JA, Sánchez-Navarro A, Remião F, Bastos ML, Carvalho F. Paraquat poisonings: Mechanisms of lung toxicity, clinical features, and treatment. *Crit Rev Toxicol.* 2008;38(1):13–71.
- Chua F, Gauldie J, Laurent GJ. Pulmonary fibrosis: Searching for model answers. *Am J Respir Cell Mol Biol.* 2005;33(1):9–13.
- Rezaie F, Khosroshahi AG, Larki-Harchegani A, Nourian A, Khosravi H. Hydroalcoholic Sumac Extract as a Protective Agent Against X-Ray-Induced Pulmonary Fibrosis. *Reports Biochem Mol Biol.* 2024;13(2):231.
- Zhi Q, Sun H, Qian X, Yang L. Edaravone, a novel antidote against lung injury and pulmonary fibrosis induced by paraquat? *Int Immunopharmacol.* 2011;11(1):96–102.
- Bertollo AG, da Silva GB, da Cunha ICE, Bagatini MD, Ignácio ZM. Redox impairment in affective disorders and therapeutic potential of phenolic bioactive compounds. In: *Natural Molecules in Neuroprotection and Neurotoxicity.* Elsevier; 2024; 121–45.
- Esmeeta A, Adhikary S, Dharshnaa V, Swarnamughi P, Ummul Maqsummiya Z, Banerjee A, et al. Plant-derived bioactive compounds in colon cancer treatment: An updated review. *Biomed Pharmacother.* 2022;153:113384.
- Alavi MS, Fanoudi S, Ghasemzadeh Rahbardar M, Mehri S, Hosseinzadeh H. An updated review of protective effects of rosemary and its active constituents against natural and chemical toxicities. *Phyther Res.* 2021;35(3):1313–28.
- Nadeem M, Imran M, Gondal TA, Imran A, Shahbaz M, Amir RM, et al. Therapeutic potential of rosmarinic acid: A comprehensive review. *Appl Sci.* 2019;9(15):3139.
- Wei Y, Chen J, Hu Y, Lu W, Zhang X, Wang R, et al. Rosmarinic Acid Mitigates Lipopolysaccharide-Induced Neuroinflammatory Responses through the Inhibition of TLR4 and CD14 Expression and NF- κ B and NLRP3 Inflammasome Activation. *Inflammation.* 2018;41(2):732–40.
- Jiang K, Ma X, Guo S, Zhang T, Zhao G, Wu H, et al. Anti-inflammatory Effects of rosmarinic Acid in Lipopolysaccharide-Induced Mastitis in Mice. *Inflammation.* 2018;41(2):437–48.
- Luo C, Zou L, Sun H, Peng J, Gao C, Bao L, et al. A Review of the Anti-Inflammatory Effects of Rosmarinic Acid on Inflammatory Diseases. *Front Pharmacol.* 2020;11:153.
- Chen Y, Nie YC, Luo YL, Lin F, Zheng YF, Cheng GH, et al. Protective effects of naringin against paraquat-induced acute lung injury and pulmonary fibrosis in mice. *Food Chem Toxicol.* 2013;58:133–40.
- Zhang X, Ma ZG, Yuan YP, Xu SC, Wei WY, Song P, et al. Rosmarinic acid attenuates cardiac fibrosis following long-term pressure overload via AMPK α /Smad3 signaling article. *Cell Death Dis.* 2018;9(2):102.
- Hejazi S, Moosavi M, Molavinia S, Mansouri E, Azadnasab R, Khodayar MJ. Epicatechin ameliorates glucose intolerance and hepatotoxicity in sodium arsenite-treated mice. *Food Chem Toxicol.* 2024;192:114950.
- Boroujeni ZZ, Khorsandi L, Zeidooni L, Badiie MS, Khodayar MJ. Protocatechuic Acid Protects Mice Against Non-Alcoholic Fatty Liver Disease by Attenuating Oxidative Stress and Improving Lipid Profile. *Reports Biochem Mol Biol.* 2024;13(2):218-230.
- Molavinia S, Goudarzi M, Azemi ME, Basir Z, Khorasgani ZN, Nooshabadi MRR, et al. Protective potential effects of hydroalcoholic extract of *Teucrium polium* L. (Lamiaceae) against Paraquat-induced lung fibrosis: An experimental study in rats. *Avicenna J Phytomedicine.* 2023;13(5):551–61.
- Rhee CK, Lee SH, Yoon HK, Kim SC, Lee SY, Kwon SS, et al. Effect of nilotinib on

- bleomycin-induced acute lung injury and pulmonary fibrosis in mice. *Respiration*. 2011;82(3):273–87.
20. Mirzaee S, Mansouri E, Shirani M, Zeinvand-Lorestani M, Khodayar MJ. Diosmin ameliorative effects on oxidative stress and fibrosis in paraquat-induced lung injury in mice. *Environ Sci Pollut Res*. 2019;26(36):36468–77.
21. Zare R, Anvari K, Mohajertehran F, Farshbaf A, Pakfetrat A, Ansari AH, et al. Association between tissue expression of toll-like receptor and some clinicopathological indices in oral squamous cell carcinoma. *Rep Biochem Mol Biol*. 2022;11(2):200-208.
22. Shen H, Wu N, Liu Z, Zhao H, Zhao M. Epigallocatechin-3-gallate alleviates paraquat-induced acute lung injury and inhibits upregulation of toll-like receptors. *Life Sci*. 2017;170:25–32.
23. Yan B, Chen F, Xu L, Xing J, Wang X. HMGB1-TLR4-IL23-IL17A axis promotes paraquat-induced acute lung injury by mediating neutrophil infiltration in mice. *Sci Rep*. 2017;7(1):597.
24. Qian J, Liu L, Chen L, Lu X, Zhu C. Increased toll-like receptor 9 expression is associated with the severity of Paraquat-induced lung injury in mice. *Hum Exp Toxicol*. 2015;34(4):430–8.
25. Shen H, Wu N, Wang Y, Zhang L, Hu X, Chen Z, et al. Toll-like receptor 9 mediates paraquat-induced acute lung injury: an in vitro and in vivo study. *Life Sci*. 2017;178:109–18.
26. Lv R, Du L, Liu X, Zhou F, Zhang Z, Zhang L. Rosmarinic acid attenuates inflammatory responses through inhibiting HMGB1/TLR4/NF- κ B signaling pathway in a mouse model of Parkinson's disease. *Life Sci*. 2019;223:158–65.
27. Yin Y, Shen H. Melatonin ameliorates acute lung injury caused by Paraquat poisoning by promoting PINK1 and BNIP3 expression. *Toxicology*. 2023;490:153506.
28. West AP, Shadel GS. Mitochondrial DNA in innate immune responses and inflammatory pathology. *Nat Rev Immunol*. 2017;17(6):363–75.
29. Phan THG, Paliogiannis P, Nasrallah GK, Giordo R, Eid AH, Fois AG, et al. Emerging cellular and molecular determinants of idiopathic pulmonary fibrosis. *Cell Mol Life Sci*. 2021;78(5):2031–57.
30. Amirshahrokhi K, Khalili AR. Carvedilol attenuates Paraquat-induced lung injury by inhibition of proinflammatory cytokines, chemokine MCP-1, NF- κ B activation and oxidative stress mediators. *Cytokine*. 2016;88:144–53.
31. Liu Z, Zhao H, Liu W, Li T, Wang Y, Zhao M. NLRP3 Inflammasome Activation Is Essential for Paraquat-Induced Acute Lung Injury. *Inflammation*. 2015;38(1):433–44.
32. Moshiri M, Mehmannaavaz F, Hashemi M, Yazdian-Robati R, Shabazi N, Etemad L. Evaluation of the efficiency of simvastatin loaded PLGA nanoparticles against acute Paraquat-intoxicated rats. *Eur J Pharm Sci*. 2022;168:106053.
33. Chu X, Ci X, He J, Jiang L, Wei M, Cao Q, et al. Effects of a natural prolyl oligopeptidase inhibitor, Rosmarinic acid, on lipopolysaccharide-induced acute lung injury in mice. *Molecules*. 2012;17(3):3586–98.